

Gamma Knife Radiosurgery for Trigeminal Neuralgia—A Review

Edward A Monaco III, MD, PhD,¹ Hideyuki Kano, MD, PhD,² Ali Kooshkabadi, MD¹ and L Dade Lunsford, MD³

1. Resident; 2. Research Assistant Professor; 3. Professor, Department of Neurological Surgery, University of Pittsburgh Medical Center

Abstract

Gamma knife radiosurgery (GKRS) evolved from the vision of Lars Leksell as a method of bloodless surgery for treating a wide variety of intracranial pathologies. Since the first GKRS procedure for trigeminal neuralgia (TN) in the early 1970s, thousands of medically refractory patients have been treated, with good results. GKRS has become a first-line treatment for medically refractory TN along with microvascular decompression and percutaneous rhizotomy. GKRS offers the advantages of minimal invasiveness and extremely low risk. When recommending a surgical treatment modality for medically refractory TN, one must consider patient preferences, procedural risks, medical comorbidities, and the success rates of the various approaches. In this context, we review the role of GKRS in the treatment of medically refractory TN.

Keywords

Trigeminal neuralgia, gamma knife, stereotactic radiosurgery, tic douloureux, facial pain

Disclosure: The authors have no conflicts of interest to declare.

Received: November 17, 2011 **Accepted:** December 19, 2011 **Citation:** *US Neurology*, 2011;7(2):149–53 DOI: 10.17925/USN.2011.07.02.149

Correspondence: L Dade Lunsford, MD, Department of Neurological Surgery, University of Pittsburgh Medical Center Presbyterian Hospital, Suite B-400, 200 Lothrop Street, Pittsburgh, PA 15213. E: lunsfordld@upmc.edu

What is Trigeminal Neuralgia?

Trigeminal neuralgia (TN) is a vexing clinical problem for a number of reasons, not least of which is clearly defining its clinical spectrum. A commonly accepted definition of TN is that of a facial pain syndrome in which a patient experiences brief, episodic, and sharp attacks of pain in the distribution of the trigeminal nerve. These painful attacks are typically unilateral but can rarely be bilateral. Painful attacks are often brought on by triggers including chewing or touching the affected dermatome. Atypical TN includes more lingering or non-episodic constant pain that does not have the typical tactile triggers. Moreover, atypical facial pain, often bilateral, can present in the context of somatoform disorders in which no organic cause can be identified. Finally, one or more of these different types of pain can be present in the same patient at the same time. It is important to distinguish between these different types of facial pain because their etiologies are probably different, and thus their treatments as well.

Burchiel's recent classification scheme, with minor modifications, links the nature of the trigeminal pain with possible mechanisms (see *Table 1*).¹ In this scheme, what has been known as tic douloureux or typical (type 1) TN is characterized by primarily episodic painful attacks located in the distribution of the trigeminal nerve branches. When constant or lingering pain is the predominant feature but there are additional episodic features, the syndrome is called type 2 TN. These idiopathic forms are distinguished from the deafferentation pain syndromes caused by either unintentional (i.e. accidental trauma) or intentional (purposeful surgical injury to the nerve) damage to the trigeminal nerve. Facial pain following a herpes zoster outbreak falls into this condition as well. These latter conditions are

associated with demonstrable trigeminal sensory loss. Finally, somatoform facial pain is labeled atypical facial pain, and is characterized by its bilaterality, as well as presence of pain well outside of the innervation of the trigeminal nerve. Unless otherwise specified, this article is focused on the paroxysmal trigeminal pain syndromes including types 1 and 2 TN as well as TN caused by multiple sclerosis (MS). None of the therapies covered in this article has meaningful benefit for constant or deafferentation facial pain.

Although TN has an annual incidence of 27 per 100,000,² the mechanism underlying its episodic facial pain remains incompletely understood. In many patients, it is related to vascular compression of the trigeminal nerve by branches of the superior cerebellar artery^{3,4} or, less commonly, adjacent veins. How this mediates pain transmission is not clear, but it has been postulated that vascular compression results in local demyelination and axonopathy, which results in ephaptic transmission between the damaged heavily myelinated fibers and the smaller unmyelinated pain fibers.⁵ This finding has led to the use of microvascular decompression (MVD) surgery as a primary treatment for TN, one that attacks the etiology in a significant number of patients. Patients with MS suffer from TN at a rate several-fold higher than the general population (2 %).⁶ Demyelination along the trigeminal system due to the underlying autoimmune phenomenon is implicated, but whether ephaptic transmission or hyperexcitability of the trigeminal nucleus actually causes the episodic pain remains unproven.⁷ Because TN in MS does not feature vascular compression as its cause, it requires a different treatment approach. Finally, deafferentation syndromes of the trigeminal nerve are the result of nerve injury, not simply

Table 1: A Modified Burchiel Facial Pain Classification System

Diagnosis	Description
Idiopathic	
Type 1 trigeminal neuralgia	>50 % episodic pain
Type 2 trigeminal neuralgia	>50 % constant pain
Trigeminal injury	
Deafferentation pain	Secondary to unintentional or intentional nerve injury
Multiple sclerosis trigeminal neuralgia	Demyelination of trigeminal system
Post-herpetic neuralgia	Following herpes zoster outbreak
Other	
Atypical facial pain	Somatoform facial pain disorder

demyelination, and are analogous to phantom limb pain. The etiologies of typical tic douloureux include vascular cross-compression as well as demyelinating events in the context of MS. The various etiologies require different treatment options. Depending on the pain syndrome, various treatment strategies may work well for some, but not all patients.

Treatment Options for Trigeminal Neuralgia

The first-line management for TN is medical therapy. Typical initial oral agents include carbamazepine, oxcarbazepine, gabapentin, phenytoin, and baclofen, used alone or in combination. The effectiveness of medications typically wanes over time despite increasing doses, with many patients not able to tolerate side effects.⁸ Eventually, as many as 50 % of TN patients can be labeled as medically refractory and require alternative management for pain relief.⁹ Surgical treatment options for TN fit on a spectrum of invasiveness and risk from MVD (most invasive, highest risk) to gamma knife radiosurgery (GKRS) (least invasive, lowest risk). Treatment of these medically refractory patients needs to be tailored with consideration given to patient age, medical comorbidities, severity of symptoms, and personal preference.

The goal of surgical management of TN is to achieve pain control and yet minimize risks. Surgeons must balance surgical risks, preservation of trigeminal sensation, and hopefully eliminate the need for continued medication use. The first successful open surgical therapy for TN involved sectioning the trigeminal nerve at one of a number of locations, the most popular and successful approach being the subtemporal approach for retrogasserian neurectomy.¹⁰ Walter Dandy is first credited with suggesting that vascular compression of the trigeminal nerve was the etiology of TN.¹¹ However, it was Peter Jannetta, with the use of the operating microscope, who demonstrated the utility of vascular decompression.³ Although not initially meeting with widespread acceptance, the long-term success of MVD has led to it becoming the treatment of choice if a craniotomy is feasible. In a large surgical series, 80 % of patients experienced complete pain relief immediately after MVD, with nearly another 10 % having partial relief.⁴ These results have proved durable: at one year, 75 % of patients report excellent results (defined as 98 % decrease in pain and off medications) with another 9 % reporting a good outcome (a 75 % decrease in pain and on low-dose medication). At 10 years, 64 % continued to have excellent outcomes, while 4 % had good outcomes. However, the major complication rate following MVD was around 8 %, including permanent neurological deficit, cerebrospinal fluid leak, bacterial meningitis, and death. Thus, although MVD is a highly effective therapy and patients often

respond immediately, it has associated risks that relate in part to the experience and skill of the surgeon who performs the procedure. Unfortunately, due to advanced age or medical comorbidities, not all patients are candidates for MVD.¹²

For patients who are unable or unwilling to tolerate the risks associated with MVD, several different percutaneous rhizotomy procedures are available. The first percutaneous therapy directed at the gasserian ganglion is credited to Harris in 1910.¹³ These first procedures involved the injection of alcohol into the ganglion and were successful in producing pain relief but at the expense of often profound anesthesia of the face and resultant deafferentation pain in some patients. Recurrences of TN were treated by additional injections when necessary.¹³ Unfortunately, this early technique was associated with other potential morbidity, including spread of the alcohol within the cerebrospinal fluid and resultant damage to other cranial nerves. This type of procedure evolved further when Häkanson inadvertently discovered that injection of glycerol, a much weaker neurolytic alcohol, produced symptomatic relief of TN.¹⁴ Specifically, glycerol is confined to the trigeminal cistern by actually measuring the cistern volume using non-ionic contrast media to perform cisternography.

Other techniques that use a transfacial percutaneous approach to the trigeminal cistern include radiofrequency rhizotomy and balloon microcompression. In our experience at the University of Pittsburgh, 1,174 patients underwent percutaneous retrogasserian glycerol rhizotomy. Ninety per cent of patients achieved early complete pain relief.¹⁵ With longer-term follow-up out to 11 years, persistent pain control was achieved in 77 % of patients; 55 % were able to eliminate medication and 22 % had pain control but still required some medicine.¹⁶ Kanpolat et al. treated 1,600 TN patients with radiofrequency rhizotomy.¹⁷ After five years, 58 % were pain-free and 42 % had recurred pain. At 20-year follow-up, 41 % of patients remained pain-free. The advantage of the percutaneous techniques is that they possess intrinsically less surgical risk, offer immediate or near-immediate pain relief, and are repeatable. However, there are patients who are not candidates, including those with medical conditions requiring long-term anticoagulation or antiplatelet agents. Percutaneous radiofrequency rhizotomy is also associated with the risk of a diminished corneal reflex, masseter weakness, anesthesia dolorosa, aseptic meningitis, and herpes simplex reactivation.

Gamma Knife Radiosurgery for Trigeminal Neuralgia

Since the development of the gamma knife in the 1960s by Leksell and Larsson, the technology has evolved tremendously. All gamma knife instruments are based on the same fundamental principle: closed-cranial irradiation of intracranial targets using multiple photon beams after localization of the target(s) in stereotactic space.¹⁸ Each unit possesses either 192 or 201 radioactive cobalt-60 sources that are spherically arrayed via collimator helmets to focus their beams to a center point. The procedure begins with application of a stereotactic frame to the head. Treatment planning images are then obtained, typically by magnetic resonance imaging (MRI) or, if contraindicated, computed tomography (CT). Finally, the actual treatment consists of the patient lying on a couch with his or her head in the stereotactic frame rigidly attached to the instrument. The patient is then placed in the focus of the chosen beams which converge on the target.

GKRS was first used by Leksell to treat TN in 1971.¹⁹ Since this initial experience, GKRS has been used to treat TN in thousands of patients worldwide. Unlike other TN treatments, GKRS is effectively non-invasive. It is similar to the percutaneous techniques in that its mechanism treats the trigeminal nerve through lesioning and bypasses the cause (i.e. vascular compression). Interestingly, although GKRS is very effective at eliminating the paroxysmal pain of TN, the risk of facial anesthesia or dysesthesias is low. It was originally suggested that the mechanism of action was a selective effect of radiation on certain populations of axons. Following irradiation of the trigeminal nerve by GKRS, MRI shows evidence of contrast enhancement at the radiosurgical target site.²⁰ Histological evaluation of the trigeminal nerve in primates following GKRS showed axonal degeneration and mild edema, with both large and small myelinated and unmyelinated axons seeing effects.²⁰ After a high radiation dose (100 Gy), nerve necrosis was identified. Thus these data demonstrated the effect of GKRS is non-selective.

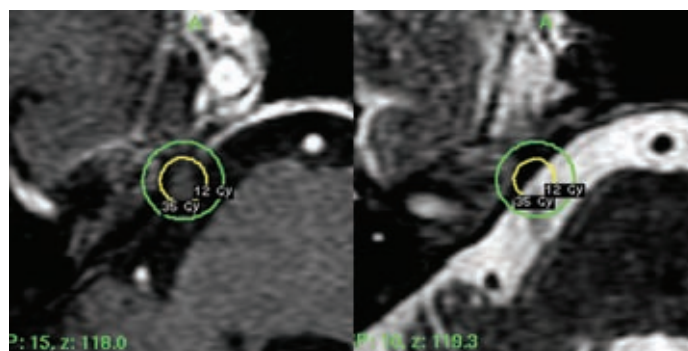
Our experience at the University of Pittsburgh treating TN with GKRS has spanned nearly three decades. In our recent report by Kondziolka et al. we reviewed our 25-year experience in over 500 medically refractory patients with idiopathic TN.²¹ The median age of this cohort was 72 and nearly half had recurrent pain after previous procedures. Although the gasserian ganglion had previously been the radiosurgical target, the most common target at present is the cisternal portion of the trigeminal nerve. Specifically, the nerve was targeted 3–8 mm distal to its exit site from the pons. In the majority of patients, a single 4 mm isocenter was targeted to the nerve and a dose of 80–85 Gy was administered (see *Figure 1*). In order to compare results across studies, many investigators have adopted the Barrow Neurological Institute (BNI) score as a standardized vehicle to indicate the success of a radiosurgical treatment (see *Table 2*).²² Following GKRS, 89 % of patients initially responded to treatment (BNI scores I–IIIb) with a median latency of one month. Only 11 % failed to achieve a good result (BNI scores IV and V). Forty per cent of the responding patients achieved complete pain relief (BNI score I). Results were durable in most patients but tended to decline as follow-up lengthened. The probabilities of maintaining adequate pain relief (BNI scores I–IIIb) at one, two, five, and 10 years were 80, 71, 46, and 30 %, respectively. Pain recurred in 193 patients (38 %) after a median of about two years, but only 147 (29 %) required additional surgical treatment for better pain control. We observed no early complications related to GKRS. Around 10 % of patients eventually developed increased facial sensory dysfunction in the form of paresthesias or sensory loss. Interestingly, patients who developed worsened facial sensory dysfunction had a significantly lower rate of pain recurrence (19 % of these patients recurred). Only one patient developed deafferentation pain (anesthesia dolorosa, 0.2 %) and this patient had pre-existing sensory loss after an MVD done prior to GKRS. Overall, most patients experienced good pain relief and had very low associated morbidity. Similar results have been reported in other large series.^{23–25}

Several avenues of investigation have been taken in an attempt to improve upon results with GKRS. Pollock et al. sought to improve patient pain relief through dose escalation.²⁶ In this study, patients receiving 70 Gy were compared with those receiving 90 Gy. With the higher dose there was a significant reduction in treatment failure, with a trend toward improved pain control. However, 90 Gy resulted in a significant increase in permanent sensory dysfunction (54 versus 15 %) with 32 % of patients developing bothersome dysesthesias. The conclusion of this study was that dose

Table 2: The Barrow Neurological Institute Score

Grade	Result
I	No trigeminal neuralgia pain, requires no medication
II	Occasional pain, requires no medication
IIIa	No pain, requires continued medication
IIIb	Some pain, controlled adequately with medication
IV	Pain improved, but not adequately controlled with medication
V	Continued severe pain without relief

Figure 1: Axial Magnetic Resonance Imaging Images (Left T1 and Right T2) Showing the Radiosurgical Target at the Right Trigeminal Nerve in a Patient with Trigeminal Neuralgia



The inner circle represents the 50 % isodose line (35 Gy) and the outer circle shows the 12 Gy line.

prescription should be kept below 90 Gy. Flickinger et al. performed a prospective double-blind, randomized trial comparing short- and long-segment GKRS for TN.²⁷ Patients were treated with either one or two 4 mm isocenters to the cisternal segment of the trigeminal nerve. Although pain relief rates were similar between the two groups, there was increased facial numbness and bothersome paresthesias in the two-isocenter group. Thus single isocenter treatments are favored. Other groups have evaluated whether proximal or distal target sites improve outcome or change complication rates.^{28–30} Matsuda et al. performed the only comparison, although retrospective in nature, between anterior and posterior targeting of the trigeminal nerve.³⁰ They observed that with posterior targeting of the nerve patients had improved early pain relief and a lower rate of complications. However, other groups advocate for anterior cisternal targeting because of its improved pain relief and low complication rate.^{28,29} Thus, this question remains unanswered. It is our routine to target the nerve 3–8 mm anterior to the junction of the nerve with the pons such that the brainstem surface is irradiated at the 20 % isodose line or less.²¹ The target is based on the variable distance between the pons and the cavernous sinus with the goal of minimizing the dose to the lateral pons.

Which Patients Should Receive Which Therapy?

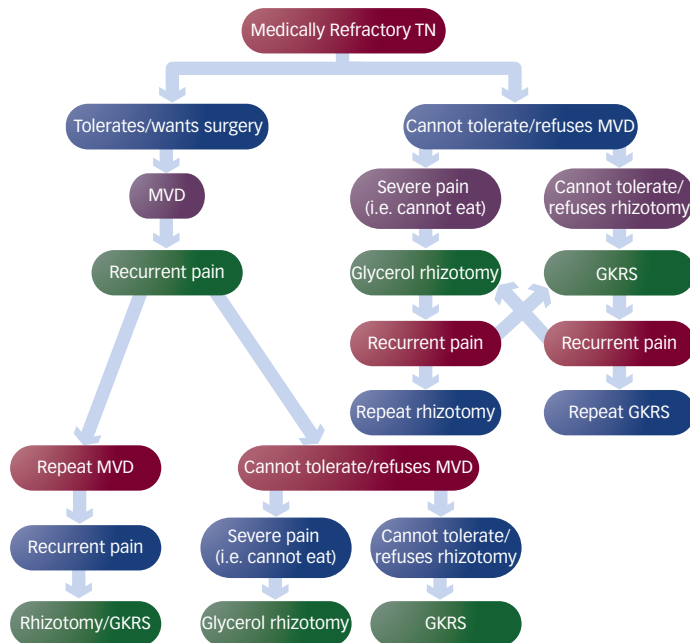
Choosing which patients should undergo GKRS for TN requires consideration of a number of factors including the suspected pain etiology, patient age, surgical fitness, previous treatments, severity of pain, patient preference, and understanding of each technique's success and complication rates. Ten years after initial MVD for medically refractory TN, 64 % of patients continue to have nearly complete relief of pain without the need for medication.⁴ This is twice the rate of durable pain relief for GKRS after 10 years.²¹ Cohort analyses comparing the efficacy of

Table 3: Treatment Outcomes After Gamma Knife Radiosurgery for Idiopathic and Multiple Sclerosis-related Trigeminal Neuralgia at the University of Pittsburgh

Outcome	Idiopathic Trigeminal Neuralgia	MS-related Trigeminal Neuralgia
Complete pain relief (BNI score I)	40 %	62 %
BNI scores I-IIIb relief	89 %	97 %
Time to pain relief (median)	One month	10 days
BNI scores I-IIIb relief at:		
One year	80 %	83 %
Three years	NR	74 %
Five years	46 %	54 %
Pain recurrent rate	38 %	38 %
Time to recurrence (median)	48 months	75 months
Facial sensory dysfunction	11 %	5 %
Anesthesia dolorosa	None	None

BNI = Barrow Neurological Institute; MS = multiple sclerosis; NR = not reported.

Figure 2: Flow Diagram Depicting a Suggested Approach to the Management of Medically Refractory Type 1 Trigeminal Neuralgia



GKRS = gamma knife radiosurgery; MVD = microvascular decompression; TN = trigeminal neuralgia.

MVD versus GKRS have shown that MVD is superior to GKRS in achieving long-lasting pain relief.³¹⁻³³ Rates of sensory dysfunction were comparable, but patients undergoing GKRS were not exposed to any of the surgical morbidities. Another important difference lies in the rapidity with which relief takes effect. Following MVD, most patients have immediate relief (i.e. upon waking from anesthesia),⁴ while the median time to pain relief following GKRS is approximately one month.²¹

MVD has also proven more effective in achieving complete and long-lasting pain relief when compared with percutaneous lesioning techniques. Tronnier et al. retrospectively compared MVD with percutaneous radiofrequency lesioning.³⁴ They found that with radiofrequency lesioning

there was a 50 % risk of pain recurrence after two years, whereas 64 % of patients undergoing MVD were still pain-free after 20 years. A meta-analysis of 28 studies confirmed that MVD was superior to radiofrequency lesioning.³⁵ Taken together with the accepted vascular compression mechanism of TN, these results suggest that, for patients who are surgically fit and willing to accept the risks of surgery, MVD is the best approach to achieve long-lasting pain relief.

Henson et al. compared their results with glycerol rhizotomy and GKRS.³⁶ They observed that both procedures provided similar early pain relief rates (86 versus 92 %, respectively, for glycerol rhizotomy and GKRS), but that glycerol rhizotomy provided more rapid pain relief (<24 hours). However, glycerol rhizotomy failed significantly more frequently in the long term and was associated with more facial sensory disturbance. Percutaneous radiofrequency lesioning has similar rates of pain control (58 % pain-free after five years) but, like glycerol rhizotomy, possesses an increased risk of facial sensory dysfunction and dysesthesias.^{36,17} Overall, percutaneous rhizotomy approaches achieve a more rapid onset of pain relief (i.e. immediate or within days), whereas GKRS takes around a month to take effect. In addition, although GKRS appears have a lower rate of long-term pain relief versus percutaneous approaches (i.e. 29 versus 52 %, respectively, long-term pain-free rate for GKRS and radiofrequency rhizotomy),^{21,17} GKRS has a greatly reduced risk of facial sensory dysfunction (i.e. 30 versus 54 %, respectively, for GKRS versus glycerol rhizotomy).³⁶ We recommend the use of percutaneous procedures in patients not medically fit for MVD and for whom pain is so severe that the latency period of GKRS is unacceptable.¹⁵

The mechanism of TN in MS is felt to be related to autoimmune-mediated demyelination at points along the trigeminal system. Although there may be evidence of vascular compression on imaging or at the time of posterior fossa exploration, the results of MVD for MS-related TN have been disappointing.^{37,38} Percutaneous techniques have been used for TN in MS patients for many years, but results are not as good as those in non-MS patients. As MS patients often have comorbidities that preclude open surgical intervention, GKRS is an ideal, minimally invasive approach. In our series, 97 % of patients achieved BNI score I-IIIb pain control following GKRS for MS-related TN.³⁹ Sixty-two per cent of patients achieved complete pain control off medications (BNI score I). BNI score I-IIIb pain control was maintained at rates of 82, 74, and 54 % after one, three, and five years, respectively. Pain recurred in 38 % of patients after a median of 75 months. Only two patients in our series developed facial sensory dysfunction (5 %) and none developed anesthesia dolorosa. These results compare favorably with our experience in treating idiopathic forms of TN (see Table 3).²¹ Similar findings have been observed in small cohorts by other groups.^{40,41} The advantage of GKRS in the setting of MS is its exquisitely low risk of complications, even when compared with the percutaneous techniques.

GKRS also has a role in the treatment of TN from other, less common causes. For example, vascular compression of the trigeminal nerve can be caused by vertebralbasilar ectasia (VBE) in up to 2 % of cases.⁴² MVD in these circumstances has proven to be the most efficacious (i.e. in one series 96, 92, and 86 % pain-free rates at one, three, and 10 years after the procedure, respectively),⁴³ but it can be technically more challenging. As a result, a high rate of surgical complications has been

observed (11 % rate of new permanent neurological deficits).⁴³ Park et al. explored the role of GKRS as a minimally invasive alternative in TN caused by VBE.² In this study of 20 patients, only 30 % achieved BNI score I pain control, while 75 % achieved BNI scores I–IIIb pain control. Sixty per cent had pain recurrence, while 10 % developed facial sensory dysfunction. Long-term pain control (BNI scores I–IIIb) rates were 53, 20, and 10 % at one, three, and five years, respectively. These results are not as good as those for patients without VBE but, due to the minimal rate of complications, GKRS should be considered as a reasonable option for these patients.

TN often recurs regardless of treatment approach. At least one-quarter of patients have pain recurrence after an initial MVD.⁴ We have observed a recurrence rate of one-quarter to one-third in patients treated by glycerol rhizotomy⁴⁴ and approximately 40 % in patients treated by GKRS.²¹ Thus, patients often require multimodality therapy and repeat procedures, even repeat GKRS. Park et al. evaluated the validity of a repeat GKRS strategy after previous failed GKRS treatment for TN in 119 patients.² In this cohort, 54 % of patients had undergone previous surgical procedures in addition to their first GKRS procedure. Following repeat GKRS, 32 % achieved complete pain relief (BNI score I) and 87 % achieved BNI scores I–IIIb pain control after a median latency of 1.5 months. Although 34 % of patients had pain recurrence, long-term pain control (BNI scores I–IIIb) was achieved in 88, 70, and 44 % of patients after one, three, and five years, respectively. Twenty-one per cent of patients developed new or worsened facial sensory dysfunction, a rate twice the

original procedure. Patients who had good relief from the initial GKRS procedure and those with some degree of facial sensory dysfunction had improved outcomes after repeat GKRS. These results suggest that repeat GKRS is a useful treatment modality, but is associated with an increased risk of facial sensory dysfunction.

Conclusions

TN is a debilitating condition for its sufferers and its management is, at times, not straightforward. Many patients will fail medical management and request some sort of surgical intervention. The vascular compression theory is well accepted and MVD has proven the most efficacious and longest lasting of the surgical options, but it is the most invasive and involves the greatest intrinsic risks. When patients are willing to accept these risks and can tolerate surgery, we recommend MVD. Percutaneous procedures involve less risk than open posterior fossa surgery and they offer relief in a similar immediate fashion, but are less efficacious and can result in a meaningful degree of facial sensory dysfunction. We offer percutaneous glycerol rhizotomy to patients with severe pain, where the latency of GKRS is unacceptable. GKRS is a first-line treatment for TN in patients unwilling or unable to tolerate open procedures or when open procedures have no role (i.e. MVD for MS-related TN). It offers patients an opportunity for meaningful long-lasting pain relief with virtually none of the risks of open surgery and it can be repeated with similar effectiveness. *Figure 2* depicts our typical treatment algorithm for TN. Low-risk pain relief and preservation of trigeminal sensation are both appropriate goals for the management of TN. ■

- Burchiel K, A new classification for facial pain, *Neurosurgery*, 2003;53:1164–7.
- Park KJ, Kondziolka D, Kano H, et al., Outcomes of gamma knife surgery for trigeminal neuralgia secondary to vertebrobasilar ectasia, *J Neurosurg*, 2012;116:73–81.
- Jannetta PJ, Arterial compression of the trigeminal nerve at the pons in patients with trigeminal neuralgia, *J Neurosurg*, 1967;26(Suppl.):159–62.
- Barker FG II, Jannetta PJ, Bissonette DJ, et al., The long-term outcome of microvascular decompression for trigeminal neuralgia, *N Engl J Med*, 1996;334:1077–83.
- Hilton DA, Love S, Gradidge T, Coakham HB, Pathological findings associated with trigeminal neuralgia caused by vascular compression, *Neurosurgery*, 1994;35:299–303.
- Brisman R, Trigeminal neuralgia and multiple sclerosis, *Arch Neurol*, 1987;44:379–81.
- Iragui VJ, Wiederholt WC, Romine JS, Evoked potentials in trigeminal neuralgia associated with multiple sclerosis, *Arch Neurol*, 1986;43:444–6.
- Taylor JC, Brauer S, Espir ML, Long-term treatment of trigeminal neuralgia with carbamazepine, *Postgrad Med J*, 1981;57:16–8.
- Katusic S, Beard CM, Bergstralh E, Kurland LT, Incidence and clinical features of trigeminal neuralgia, Rochester, Minnesota, 1945–1984, *Ann Neurol*, 1990;27:89–95.
- Cole CD, Liu JK, Apfelbaum RI, Historical perspectives on the diagnosis and treatment of trigeminal neuralgia, *Neurosurg Focus*, 2005;18:E4.
- Dandy WE, The brain. In: Walters W, Ellis FH Jr (eds), *Lewis-Walters' Practice of Surgery*, Volume 12, Hagerstown, MD: WF Prior, 1963;1–671.
- Oh IH, Choi SK, Park BJ, et al., The treatment outcome of elderly patients with idiopathic trigeminal neuralgia: micro-vascular decompression versus gamma knife radiosurgery, *J Korean Neurosurg Soc*, 2008;44:199–204.
- Harris W, An analysis of 1,433 cases of paroxysmal trigeminal neuralgia (trigeminal-tic) and the end-results of gasserian alcohol injection, *Brain*, 1940;63:209–24.
- Häkanson S, Trigeminal neuralgia treated by the injection of glycerol into the trigeminal cistern, *Neurosurgery*, 1981;9:638–46.
- Kondziolka D, Lunsford LD, Percutaneous retrogasserian glycerol rhizotomy for trigeminal neuralgia: technique and expectations, *Neurosurg Focus*, 2005;18:E7.
- Jho HD, Lunsford LD, Percutaneous retrogasserian glycerol rhizotomy. Current technique and results, *Neurosurg Clin N Am*, 1997;8:63–74.
- Kanpolat Y, Savas A, Bekar A, Berk C, Percutaneous controlled radiofrequency trigeminal rhizotomy for the treatment of idiopathic trigeminal neuralgia: 25-year experience with 1,600 patients, *Neurosurgery*, 2001;48:524–34.
- Lunsford LD, Flickinger J, Lindner G, Maitz A, Stereotactic radiosurgery of the brain using the first United States 201 cobalt-60 source Gamma Knife, *Neurosurgery*, 1989;24:151–9.
- Leksell L, Stereotaxic radiosurgery in trigeminal neuralgia, *Acta Chir Scand*, 1971;137:311–4.
- Kondziolka D, Lacomis D, Niranjana A, et al., Histological effects of trigeminal nerve radiosurgery in a primate model: implications for trigeminal neuralgia recovery, *Neurosurgery*, 2000;46:971–7.
- Kondziolka D, Zorro O, Lobato-Polo J, et al., Gamma knife stereotactic radiosurgery for idiopathic trigeminal neuralgia, *J Neurosurg*, 2010;112:758–65.
- Rogers CL, Shetter AG, Fiedler JA, et al., Gamma Knife radiosurgery for trigeminal neuralgia: the initial experience of the Barrow Neurological Institute, *Int J Radiat Oncol Biol Phys*, 2000;47:1013–9.
- Pollock BE, Phuung LK, Gorman DA, et al., Stereotactic radiosurgery for idiopathic trigeminal neuralgia, *J Neurosurg*, 2002;97:347–53.
- Sheehan J, Pan H, Stroila M, Steiner L, Gamma knife surgery for trigeminal neuralgia: outcomes and prognostic factors, *J Neurosurg*, 2005;102:434–41.
- Régis J, Arkha Y, Yomo S, et al., [Radiosurgery in trigeminal neuralgia: long-term results and influence of operative nuances], *Neurochirurgie*, 2009;55:213–22.
- Pollock BE, Phuung LK, Foote RL, et al., High-dose trigeminal neuralgia radiosurgery associated with increased risk of trigeminal nerve dysfunction, *Neurosurgery*, 2001;49:58–62; discussion 62–4.
- Flickinger JC, Pollock BE, Kondziolka D, et al., Does increased nerve length within the treatment volume improve trigeminal neuralgia radiosurgery? A prospective double blind, randomized study, *Int J Radiat Oncol Biol Phys*, 2001;51:449–54.
- Massager N, Lorenzoni J, Devriendt D, et al., Gamma Knife surgery for idiopathic trigeminal neuralgia using a far-anterior cisternal target and a high dose of radiation, *J Neurosurg*, 2004;100:597–605.
- Régis J, Metellus P, Hayashi M, et al., Prospective controlled trial of Gamma Knife surgery for essential trigeminal neuralgia, *J Neurosurg*, 2006;104:913–24.
- Matsuda S, Serizawa T, Nagano O, Ono J, Comparison of the results of 2 targeting methods in Gamma Knife surgery for trigeminal neuralgia, *J Neurosurg*, 2008;109(Suppl.):185–9.
- Brisman R, Microvascular decompression vs. Gamma Knife for typical trigeminal neuralgia: preliminary findings, *Stereotact Funct Neurosurg*, 2007;85:94–8.
- Linskey ME, Ratanatharathorn V, Penagarciano J, A prospective cohort study of microvascular decompression and Gamma knife surgery in patients with trigeminal neuralgia, *J Neurosurg*, 2008;109(Suppl.):160–72.
- Pollock BE, Schoeberl KA, Prospective comparison of posterior fossa exploration and stereotactic radiosurgery dorsal root entry zone target as a primary surgery for patients with idiopathic trigeminal neuralgia, *Neurosurgery*, 2010;67:633–9.
- Tronnier VM, Rasche D, Hamer J, et al., Treatment of idiopathic trigeminal neuralgia: comparison of long-term outcomes after radiofrequency rhizotomy and microvascular decompression, *Neurosurgery*, 2001;48:1261–7; discussion 1267–8.
- Tatli M, Satici O, Kanpolat Y, Sindou M, Various surgical modalities for trigeminal neuralgia: literature study of respective long-term outcomes, *Acta Neurochir (Wien)*, 2008;150:243–55.
- Henson CF, Goldman HW, Rosenwasser RH, et al., Glycerol rhizotomy versus gamma knife radiosurgery for the treatment of trigeminal neuralgia: an analysis of patients treated at one institution, *Int J Radiat Oncol Biol Phys*, 2005;63:82–90.
- Resnick DK, Jannetta PJ, Lunsford LD, Bissonette DJ, Microvascular decompression for trigeminal neuralgia in patients with multiple sclerosis, *Surg Neurol*, 1996;46:358–61.
- Broggi G, Ferroli P, Franzini A, et al., Operative findings and outcomes of microvascular decompression for trigeminal neuralgia in 35 patients affected by multiple sclerosis, *Neurosurgery*, 2004;55:830–8.
- Zorro O, Lobato-Polo J, Kano H, et al., Gamma knife radiosurgery for multiple sclerosis-related trigeminal neuralgia, *Neurology*, 2009;73:1149–54.
- Rogers CL, Shetter AG, Ponce FA, et al., Gamma knife radiosurgery for trigeminal neuralgia associated with multiple sclerosis, *J Neurosurg*, 2002;97(5 Suppl.):529–32.
- Huang E, Teh BS, Zeck O, et al., Gamma knife radiosurgery for treatment of trigeminal neuralgia in multiple sclerosis patients, *Stereotact Funct Neurosurg*, 2002;79:44–50.
- Lopez BC, Hamlyn PJ, Zakrzewska JM, Systematic review of ablative neurosurgical techniques for the treatment of trigeminal neuralgia, *Neurosurgery*, 2004;54:973–83.
- Miyazaki S, Fukushima T, Tamagawa T, Morita A, [Trigeminal neuralgia due to compression of the trigeminal root by a basilar artery trunk. Report of 45 cases], *Neurol Med Chir (Tokyo)*, 1987;27:742–8.
- Kondziolka D, Lunsford LD, Bissonette DJ, Long-term results after glycerol rhizotomy for multiple sclerosis-related trigeminal neuralgia, *Can J Neurol Sci*, 1994;21:137–40.