

# Which Electroencephalogram Patterns Are Commonly Misread as Epileptiform?

a report by

Steve Winesett<sup>1</sup> and Selim R Benbadis<sup>2</sup>

1. Assistant Professor of Neurosurgery; 2. Professor of Neurology, University of South Florida

DOI:10.17925/ENR.2008.03.02.101

The accurate diagnosis of epilepsy is difficult. Studies in tertiary epilepsy centres have shown that 30% of adult patients referred for intractable 'epilepsy' have non-epileptic events, chiefly psychogenic non-epileptic spells (PNES).<sup>1</sup> Likewise, in paediatric epilepsy centres 15–39% have non-epileptic paroxysmal events.<sup>2,3</sup> The electroencephalogram (EEG) can be both helpful and misleading in diagnosis. In children, up to 6.8% will have true epileptiform discharges without clinical epilepsy when photic stimulation is used.<sup>4,5</sup> In adults, the percentage is much lower, probably less than 2%.<sup>6,7</sup> Studies from the early years of EEG showed higher percentages, usually around 2–4%, because they included 6 and 14Hz positive spikes or six-per-second waves as epileptiform.<sup>8</sup> These are widely recognised today as non-epileptogenic. Accuracy in reading EEGs is critical in both identifying patients who have an increased risk of having epilepsy and avoiding the misdiagnosis of epilepsy in patients without epilepsy.

Multiple papers have revealed that many patients with non-epileptic disorders such as syncope and PNES have the incorrect diagnosis of epilepsy perpetuated by the misreading of benign EEG patterns.<sup>9–11</sup> One-third of the patients later found to have PNES have had previous EEGs that were interpreted as epileptiform that contributed to the misdiagnosis.<sup>9</sup> When the studies were obtained and reviewed carefully, most of the misread patterns were simple fluctuations of sharply contoured background rhythms or fragmented alpha activity. Other patterns in the studies included wicket spikes, hyperventilation-induced slowing and hypnagogic hypersynchrony. The consequences of misreading EEGs are many. First, it may delay arriving at the correct diagnosis. Once a patient is 'labelled' with a diagnosis, it is difficult to undo it. It requires obtaining the original EEG and reinterpreting it. No amount of normal EEGs can undo an abnormal EEG unless this is done, and it is often difficult in clinical practice. Acceptance of the diagnosis of PNES is difficult when patients have been told that their previous EEG was 'abnormal'. This may contribute to the usual delay in diagnosis of PNES of seven years.<sup>12</sup> Unfortunately, the longer the delay in arriving at the diagnosis of PNES, the worse the prognosis.<sup>13</sup> Conservative reading of EEGs is important in avoiding misdiagnosis, which wastes society's and the patient's healthcare resources and delays proper treatment.

The reasons for misinterpretation are unclear and complex. One factor appears to be the overemphasis on 'phase reversals'. Many experts feel that the overemphasis on these and 'sharp activity' causes many problems.<sup>14,15</sup> There is a common misconception that sharp activity that points towards each other, i.e. phase reversals, is pathogenic. The basic principles of polarity and localisation make it clear that this is not true; it is only indicative of localisation of a negative discharge, much of which is totally normal. Phase reversals are not one of the criteria used to determine whether a discharge is epileptiform. Strict criteria need to be applied to determine whether a discharge is of epileptic significance. Other factors include trying too hard to find an abnormality because the patient had a 'seizure', fear of

missing an abnormality or inexperience in reading EEGs and, in particular, paediatric EEGs.

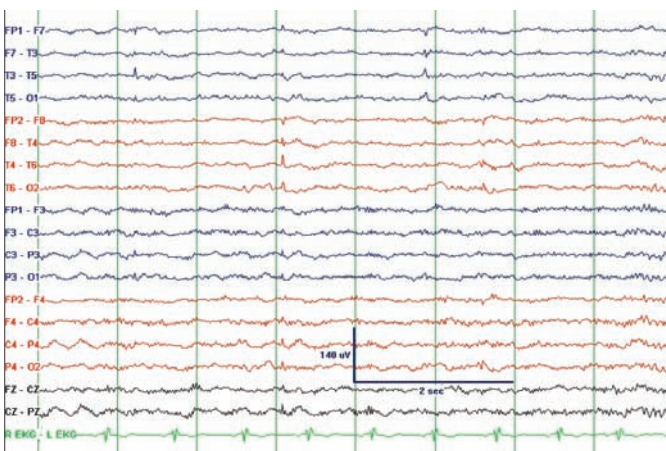
Sharp activity in order to be epileptiform needs to stand out significantly from the background (>50%) and disrupt it. This is usually in the form of a spike (<70ms) or sharp wave (70–200ms) with a slow wave that disrupts the background. Unfortunately, there is an over-reliance on phase reversals to distinguish sharp activity. This is often the source of misreading, because phase reversals are normal phenomena and when superimposed on the underlying rhythms can give the appearance of a spike and slow wave. Usually, a review of the background will help to distinguish this superimposition of rhythms from true pathological sharp activity.

The state of wakefulness or sleep is also important in the determination of pathogenicity. In general, sharp transients seen only during drowsiness or light sleep are less likely to be associated with epilepsy. In a study of sleep EEGs carried out on 'normal' patients during polysomnograms, there was an incidence of frontal sharp transients in 68%, temporal sharp transients in 37% and spike and wave discharges (predominantly frontal) in 13%. The criteria for the sharp transients were not stated clearly, but they emphasise the presence of sharply contoured waveforms in drowsiness and light sleep where most of these were found.<sup>16</sup> In contrast, studies of 'awake' EEGs show that an incidence has been found of 0.5% in Royal Air Force crews (58% of these were during photic stimulation, one of which later developed epilepsy)<sup>6</sup> and 2% in US Air Force personnel (included drowsy state).<sup>7</sup>

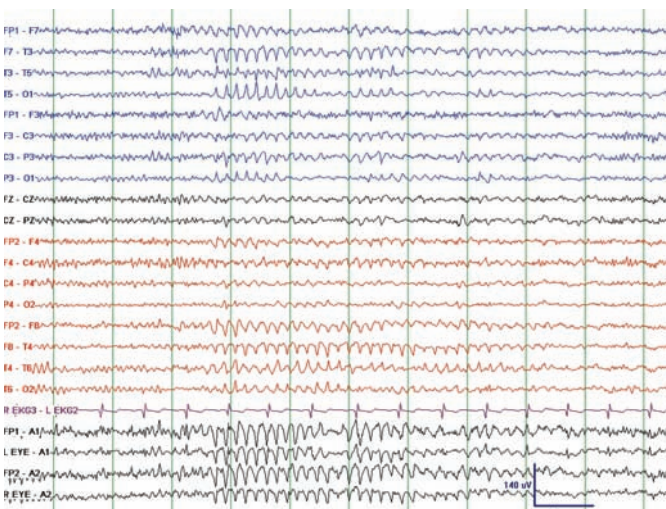
Training programmes correctly emphasise training in recognising many common variants that have caused misreading in the past. A recent study showed that these patterns have not been the cause of recent misreading in adults, but rather it is nameless rhythms such as sharply contoured and anteriorly displaced alpha rhythms that cause the most confusion in adult patients.<sup>9</sup> There has been no systematic evaluation of misreading errors in paediatric patients. Paediatric EEGs require electroencephalographers to correlate variations in both rhythms and voltage with the patient's age, which creates more opportunities for misreading. Here we will briefly discuss the commonly defined variants that have caused confusion and then discuss the nameless alphoid rhythms that appear to be the source of confusion in adult patients.

In adult patients, most of the misread patterns are temporal lobe sharp wave or spike mimics. Temporal lobe sharp wave activity has a high correlation with clinical seizures. A study of EEGs from one centre showed anterior temporal spikes to be correlated with epilepsy in 80%. Spikes from the mid-temporal and posterior temporal leads were less likely to be associated with seizures but greater than 50%.<sup>17</sup> As a result, separating these temporal lobe sharp and spike wave mimics is critical and the source of many misreading errors.

**Figure 1: Typical Small Sharp Spikes Seen Bilaterally in Light Sleep**



**Figure 2: Rhythmic Midtemporal Discharge – Also Known as the Psychomotor Variant**



## Small Sharp Spikes or Benign Epileptiform Transients of Sleep or Benign Sporadic Sleep Spikes

Small sharp spikes are found in the temporal region, usually during drowsiness or stage one or stage two sleep.<sup>15</sup> They are usually diphasic with a steep slope of the second phase and amplitude <50 microvolts. Unlike pathological temporal spikes, they do not increase but rather disappear with deeper stages of sleep. They have a short duration (<50ms) and do not disrupt the background on which they are superimposed. They also do not have a prominent slow wave and do not appear in repetitive trains. Although short EEG studies may show them only unilaterally, prolonged studies usually show them bilaterally. They are predominantly seen in adults. Studies have shown an incidence of over 20% in normal and epileptic patients.<sup>18</sup> They have no significance in the diagnosis of epilepsy. An example is shown in *Figure 1*.

## Wicket Spikes

These are fragments of the mu rhythm in the temporal region but can be confused with a pathological temporal sharp wave. These can occur singly where they have a simple morphological appearance and do not disrupt the background, or in trains of 6–11Hz arciform waves. The trains often have a crescendo–decrescendo appearance. The arciform appearance is similar to wickets, hence the name. They can be seen

predominantly on one side or on both sides. They are seen predominantly in adults and can appear in both wakefulness and sleep. Interictal epileptiform spikes and sharp waves often have a slow wave, whereas wickets generally do not, although occasionally the superimposition of a wicket on the underlying rhythms can superficially resemble a spike and slow wave. Emphasising the need to evaluate carefully for wickets, 25 patients with PNES were found at a major institution over a six-year period (1996–2002) to have had wicket patterns misinterpreted as epileptogenic on outside EEGs when, in fact, the EEGs were normal.<sup>19</sup>

## 6 and 14Hz Positive Burst Pattern or Positive Spikes or Ctenoids

These consist of positive spikes with a smooth, rounded waveform between the spikes, giving a spiky, spindle-like appearance. These are seen in up to 58% of normal teenage boys. They begin to be seen at three years of age, peak at 13–14 years of age and then decline with advancing age. They are often over the posterior temporal and parietal regions and occur unilaterally in bursts of less than one second, either unilaterally or independently, on both sides. They are best seen in referential montages. In the early years of EEG they were felt to be pathological and to be correlated with abdominal pain and headaches.<sup>20</sup> Now they are considered a normal variant and without epileptic potential.

## Rhythmic Temporal Theta Burst of Drowsiness or Psychomotor Variant

This activity is 5–7Hz rhythmic activity occurring over the temporal area. It is usually maximal over the mid-temporal regions. It may be seen unilaterally or bilaterally, or may shift from side to side. It may have a sharply contoured appearance or a notched appearance if superimposed on the background. It can simulate a seizure discharge but can be distinguished by its gradual onset and disappearance and by its monotonous morphology and lack of evolution into other frequencies (see *Figure 2*).

## Subclinical Rhythmic Electrical Discharge of Adults

This is most common in older adults and is often bilateral, but can be asymmetrical or unilateral. They can begin abruptly, sometimes with a single high-voltage sharp or slow wave component, and have evolution from slower frequencies as low as 0.5Hz to a sustained rhythmic sinusoidal pattern of 4–7Hz, but are usually 5–6Hz. They can last for seconds up to five minutes. They generally occur in wakefulness, but can also occur in sleep. They are predominantly over the parietal and posterior temporal regions and can be brought out by hyperventilation. There does not appear to be an association with epilepsy, even with prolonged follow-up.<sup>21</sup>

## Alphoid Patterns

In a recent paper, PNES patients had their ‘abnormal’ EEG obtained and reviewed. Most of the misdiagnosis of the the abnormal EEG was of sharply contoured rhythms in the temporal lobe, the result of anteriorly prominent alpha activity and nameless random fluctuations of temporal sharp activity. They can also be seen with superimposition of alpha and theta of drowsiness. There is no fundamental difference between these background fluctuations and wicket spikes.<sup>22</sup> These patterns are often confusing because of the feeling of many EEG readers that everything sharp is pathogenic or because of an over-reliance on phase reversals.<sup>14,15</sup>





movements when these are present, asking the patient to close his or her eyes, which causes them to disappear.

## Posterior Slow Waves of Sleep

These are predominantly found in children and disappear by early adulthood. They are often found embedded in the alpha activity and when superimposed on the sharply contoured alpha activity of many children can resemble spike and wave foci. They can be repetitive at times and in prolonged runs. Recognising the presence of this elsewhere in the study and the underlying alpha rhythm should help to differentiate this normal variant from pathological activity.

## Generalised Activity

### Hyperventilation

Children are hyperventilated both by activation procedures and by crying. Recognising the effect of hyperventilation during these times is helpful in avoiding misreading. Hyperventilation is quite helpful in bringing out the typical 3Hz spike and wave seen in absence epilepsy, so it is a common procedure in paediatric EEGs. Hyperventilation in normal young children can exceed 100 microvolts. Although not well quantified by voltage, an early study showed 97% of children aged three to five having a big build-up. The percentage of patients with this big build-up drops progressively as the age of the patient increases, until adulthood, where fewer than 10% have a big build-up.<sup>26</sup> These high-voltage waves associated with hyperventilation response are often notched and should not be confused with pathological spike and wave activity in which the spikes are quite dramatic. There is a wide range of normal hyperventilation response and the electroencephalographer should be cautious in calling anything but the clear 3Hz spike and wave response.

### Photic Stimulation

This activating procedure is widely used and certainly valuable. Unfortunately, there is often misinterpretation because of the lack of differentiation of the photoparoxysmal response from the photomyoclonic response. The photomyoclonic response occurs because of muscle activity from brief contractions of the eyes in response to the light flicker. It is usually anteriorly predominant but can spread to more posterior regions if other muscles are involved in the eye contractions. It is time-locked to the photic stimulus and should not outlast it. It has no relationship to epilepsy. The photoparoxysmal response is characterised by generalised spike and wave activity without a clear relationship to the light flashes. The photoparoxysmal response is associated with epilepsy.

### Hypnagogic Hypersynchrony

This rhythm is characterised by a 3–5Hz sustained, monomorphic rhythm that occurs in drowsiness. It can be seen as early as three

months and is maximally expressed at the end of the first year of life. It generally disappears by 13 years of age. The difficulty with this rhythm is that it is not always sustained and can occur in paradoxical bursts even when the child appears to be alert and awake. They can have amplitudes in excess of 350 microvolts.<sup>24</sup> This occurs maximally in four- to nine-year-olds and may have sharp or spike-like components embedded within the burst. This can appear to be 'epileptiform', but the fact that it occurs only in drowsiness or sleep onset in an otherwise normal recording should be reassuring.<sup>23</sup>

## Sleep Structures

Vertex activity in children is often quite sharp and of high amplitude. They can be widespread, involving the frontal as well as the central regions. They can be repetitive in a 0.5–1Hz pattern. They can also be asymmetrical at onset. Sleep spindles can also be asymmetrical, particularly in the first three years of life. They can vary in frequency from 11 to 14Hz and be sustained for up to four seconds.<sup>24</sup> They can be frontally predominant and high-voltage compared with adult sleep spindles. These features, particularly in infants, can produce complex patterns simulating epileptic activity. Careful attention to realising that the vertex and sleep spindles are eventually seen on both sides and only during sleep should help to differentiate them. This makes having more than a few minutes of sleep invaluable in the EEG records of children.

## Conclusion

The EEG is a powerful tool in helping to tailor therapy for patients with clinical epilepsy. The use of the EEG to distinguish generalised epilepsy from patients with focal epilepsy has survived the test of time. It is critical for deciding on the antiepileptics to use or avoid. It helps to select patients who may benefit from resective surgery. It is helpful in delineating prognosis for resolution of seizures. It can be helpful in determining patients who may need further work-up for aetiology. Unfortunately, misreading of benign EEG patterns has been implicated in causing harm to patients by delaying diagnosis and causing treatment for epilepsy with potentially harmful antiepileptic medications. It is important to be conservative in reading and insist on further or longer studies in EEGs with questionable patterns. Likewise, in this modern age of digital technology and being able to transfer EEG studies to portable media, we should not be afraid to consult with more experienced or specialised electroencephalographers rather than diagnosing the patient with an abnormal EEG. As noted in studies of PNES, once a patient has an 'abnormal' EEG, it is often difficult to obtain the study in clinical practice to undo this incorrect reading. Likewise, for electroencephalographers, it is critical in situations where an abnormal EEG does not fit the clinical situation to attempt to obtain that study and make sure it is not a misread benign EEG pattern. Just ordering another EEG does not cancel the previous 'abnormal' EEG, because pathological EEG patterns do not necessarily appear on every EEG. ■

1. Benbadis SR, Heriaud L, O'Neill E, et al. *Epilepsia*, 2004;45:1150–53.
2. Kotagal P, Costa M, Wyllie E, Wolgamuth B, *Pediatrics*, 2002;110:e46.
3. Uldall P, Alving J, Hansen LK, et al., *Arch Dis Child*, 2006;91:219–21.
4. Cavazzuti GB, Capella L, Nalin A, *Epilepsia*, 1980;21:43–55.
5. Doose H, Gerken H, Hien-volpel KF, Volzke E, *Neuropadiatrie*, 1969;1:56–73.
6. Gregory RP, Oates T, Merry RTG, *Electroencephalogr Clin Neurophysiol*, 1993;86:75–7.
7. Robin JJ, Tolan GD, Arnold JW, *Aviat Space Environ Med*, 1978;49(5):732–6.
8. Zivin L, Marsan CA, *Brain*, 1968;91:751–8.
9. Benbadis SR, Tatum WO, *J Clin Neurophysiol*, 2003;20:42–4.
10. Smith D, Defalla BA, Chadwick DW, *Q J Med*, 1999;92:15–23.
11. Zaidi A, Clough P, Cooper P, et al., *J Am Coll Cardiol*, 2000;36:181–4.
12. Reuber M, Fernandez G, Bauer J, et al., *Neurology*, 2002;58:493–5.
13. Selwa LM, Geyer J, Nikakhtar N, et al. *Epilepsia*, 2000;41:1330–34.
14. Benbadis SR, Lin K, *Eur Neurol*, 2008;59:267–71.
15. Klass DW, Westmoreland BF, *Ann Neurol*, 1985;18:627–35.
16. Beun AM, van Emde Boas W, Dekker E, *Electroencephalogr Clin Neurophysiol*, 1998;106:44–51.
17. Hughes JR, Olson SF, *Epilepsia*, 1981; 22:421–35.
18. White JC, Langston JW, Pedley TA, *Neurology*, 1997;27:1061–8.
19. Krauss GI, Abdallah A, Lesser R, et al., *Neurology*, 2005;64:1879–83.
20. Crawley J, Kellaway P, *Pediatric Clinics NA*, 1963;10:17–51.
21. Westmoreland BF, Klass DW, *Electroencephalogr Clin Neurophysiol*, 1981;51:186–91.
22. Benbadis SR, *J Clin Neurophysiol*, 2006;23:340–52.
23. Mizrahi EM, *Epilepsia*, 1996;37(Suppl. 1):S41–551.
24. Kellaway P, Fox BJ, *J Pediatr*, 1952;41:262–87.
25. Vignaendra V, Matthews RL, Chatrjian GE, *Electroencephalogr Clin Neurophysiol*, 1974;37:239–46.
26. Gibbs FA, Gibbs EL, Lennox WG, *J Peds*, 1943;23:497–505.