

Combined Use of DES, EMG and MEP Monitoring, ECoG and EEG for Surgical Resection of Gliomas

a report by

Lorenzo Bello, Enrica Fava, Giorgio Carrabba and Giulio Bertani

Department of Neurological Sciences, Università degli Studi di Milano, and Fondazione IRCCS Ospedale Maggiore Policlinico, Milan

DOI:10.17925/ENR.2008.03.01.70

Surgery for gliomas aims to remove as much of the tumour mass as possible while at the same time preserving the patient's functional integrity. This policy particularly applies to resection of gliomas located close to or within the so-called 'eloquent' areas, i.e. areas that are involved in motor, language or visuospatial functions. In these cases, extended resection and maximal functional integrity can be achieved by using a cohort of procedures that make up the so-called brain-mapping techniques. These include neuropsychological evaluation, imaging techniques such as functional magnetic resonance imaging (fMRI) and diffusion tensor imaging–fibre tracking (DTI-FT) – generally loaded into the neuronavigation system so as to be available peri-operatively – and a series of neurophysiological techniques available at the time of surgery such as cortical and subcortical direct electrical stimulation (DES), motor-evoked potentials (MEPs), multichannel electromyogram (EMG), electroencephalogram (EEG) and electrocorticogram (ECoG) recordings. In this article we will focus on these neurophysiological adjuncts by describing the protocol in use at our institution for resection of gliomas, and by discussing the rationale and indications for and the results of our experience.

Brain-mapping Protocol

The brain-mapping protocol is part of a large management protocol that includes pre- and peri-operative components. The pre-operative component comprises a comprehensive neuropsychological evaluation and an extensive neuroradiological examination. The neuropsychological evaluation consists of a large number of tests aimed at the evaluation of various functions such as cognitive, emotional, intelligence and language functions.¹⁻⁵ This broad evaluation provides information on how the tumour has influenced the social, emotional and cognitive life of the patient, who is generally intact at the neurological examination. In addition, it allows us to build up a series of tests, composed of various items, that will be used intra-operatively for the evaluation and mapping of various functions, among which memory, language in its various components and visuospatial abilities are some of the most important. The neuroradiological examination is composed of basic examinations, such as morphological T1, T2 and flair images, as well as post-contrast T1 images. These images, together with volumetric sequences,

provide information on the location of the tumour and allow its relationship with various structures – such as major vessels – to be determined and tumour volume to be measured. Other MR studies include MR spectroscopy, which provides information on the metabolic characteristics of the tumour, and perfusion MR, which is useful for designating the perfusion map of the tumour (regional blood flow dependent on tumour angiogenesis). These studies provide additional and complementary information about the biological behaviour of the tumour and help in tissue collection for histological and molecular purposes at the time of surgery.

Additional neuroradiological studies include functional studies such as fMRI and anatomical studies such as DTI-FT.⁶ The former provides functional information on the location of cortical sites that are activated in response to motor or various language tasks. Motor fMRI is generally used to create a map of the cortical motor sites and to establish their relationship with the tumour. Language fMRI provides a map of the cortical sites that are activated during various language tasks, such as object naming, famous face naming, verb generation and verbal fluency. Together, they form a complex map of how the various components of language are organised at the cortical level and allow the spatial relationship between these cortical areas of language activation and the tumour mass to be established. DTI-FT enables the connectivity around and inside a tumour to be depicted by reconstructing and visualising the fibre tracts that run around or inside the tumour mass. DTI-FT also provides anatomical information on the location of motor tracts, mainly the corticospinal tract, and various language tracts involved in either the phonological or semantic components of language, such as the superior longitudinalis, the inferior fronto occipital and the inferior longitudinalis tracts.

Pre-operative neuroimaging produces an impressive amount of data concerning the anatomical and functional boundaries of the lesion to be resected. Together with the volumetric morphological images, these data are usually loaded into the neuronavigation system and help in the peri-operative period when performing the resection. However, most of this information is based on probabilistic measurements and, although the techniques are characterised by high sensitivity or specificity, they cannot be considered sufficient for performing a safe and effective resection. This is why neuroradiological data are co-adjuvated during surgery with those provided by the neuropsychological mapping for language and visuospatial function and the neurophysiological mapping for motor functions, which ultimately represent the gold standard for preserving these functions during surgical treatment. In fact, only intra-operative brain mapping by means of electrical stimulation allows the surgeon to identify functional regions that may be displaced and infiltrated by the tumour at both a cortical and a subcortical level, and to define the strategy of resection in order to maximise the extent of tumour resection while reducing the risk of permanent motor defects.



Lorenzo Bello is an Associate Professor of Neurosurgery at the University of Milan, a position he has held since 2005. Previously, he was a Fellow in Neurosurgery and Brain Tumours at Brigham and Women's Hospital, Harvard Medical School. Professor Bello is a member of numerous associations and professional societies, including the Italian Neurosurgical Society and the European Association of Neuro-Oncology (EANO), and he serves as a member of the European Association of Neurosurgical Societies (EANS)

Research Committee. He received his MD from the University of Milan in 1990 and completed his residency in neurosurgery at the same university in 1995.

E: lorenzo.bello@unimi.it

As mentioned above, the neurophysiological protocol is part of a wider intra-operative protocol that includes anaesthesia modalities, neuro-navigation and neuropsychology. We have already provided information for neuropsychology and neuronavigation. As for anaesthesia, total intravenous anaesthesia with propofol and remifentanyl is used in our institution when performing these procedures. Patients requiring motor mapping only are intubated by the nose and a light surgical anaesthesia is maintained throughout the procedure. No muscle relaxants are employed during surgery. When language or visuospatial functions have to be assessed during surgery, the patients receive a laryngeal mask, which is maintained until after craniotomy and dural opening; at this point the patients are awakened, with adequate analgesia maintained, to allow functional evaluation. All of these techniques are complementary and are needed to reach an optimal result on both extent of resection (oncological end-point) and preservation of patient functional integrity (functional end-point).

Methodology

The major components of the neurophysiological protocol are EEG, ECoG, EMG, DES and MEP techniques. The protocol includes mapping and monitoring procedures. Methodological rigidity and meticulous performance of the mapping procedure are indispensable in order to avoid any false-positive or false-negative stimulation results, which could give rise to premature interruption of tumour resection or cause permanent neurological deficits. If all of the technical rules are not respected, false results will create a feeling of safety where there is none. This will lead to undesired surgical results and permanent neurological deficits. EEG activity is recorded bilaterally by four subdermal needle electrodes, providing four bipolar leads. EEG is recorded to monitor brain activity when ECoG is not available – i.e. at the beginning and end of surgery – and, moreover, to assess brain activity at a distance from the operating field, such as in the contralateral hemisphere.

ECoG activity from a cortical region adjacent to the area being stimulated is recorded by subdural strip electrodes with four to eight contacts in a monopolar array, referred to as midfrontal electrodes. Cerebral activity is recorded with a bandwidth of 1.6–320Hz and displayed with a sensitivity of 50–100 micron/cm for EEG and 200–400 micron/cm for ECoG. Continuous ECoG (Comet, Grass) is used throughout the procedure to check the basal brain electrical activity, to define the working current for DES (as the value immediately below that which induces an after-discharge [AD]), to check for the occurrence of ADs, i.e. seizure activity, while DES is applied or to detect the onset of seizure activity at any time during the resection.

A continuous multichannel EMG recording (Comet, Grass) is used throughout the procedure. Motor responses are collected by pairs of subdermal hooked needle electrodes. Several muscles are monitored, mostly in the contralateral but also in the ipsilateral body, from the face to the feet. Each pair of electrodes may record activity arising in a single muscle or in two antagonist muscles in the same limb in order to obtain the widest muscle sampling (i.e. a flexor and an extensor muscle in the forearm). On average, 16 channels are used for each procedure. The most frequently used muscles are those in the face (upper and lower face), tongue, soft palate, neck, arm, forearm, hand, thigh, leg and foot (see *Figure 1a*). A computerised video image system is continuously coupled with the EMG recordings to register motor activity. In addition to EMG recordings, motor activity is also monitored visually, and is clinically tested at intervals in awake patients.

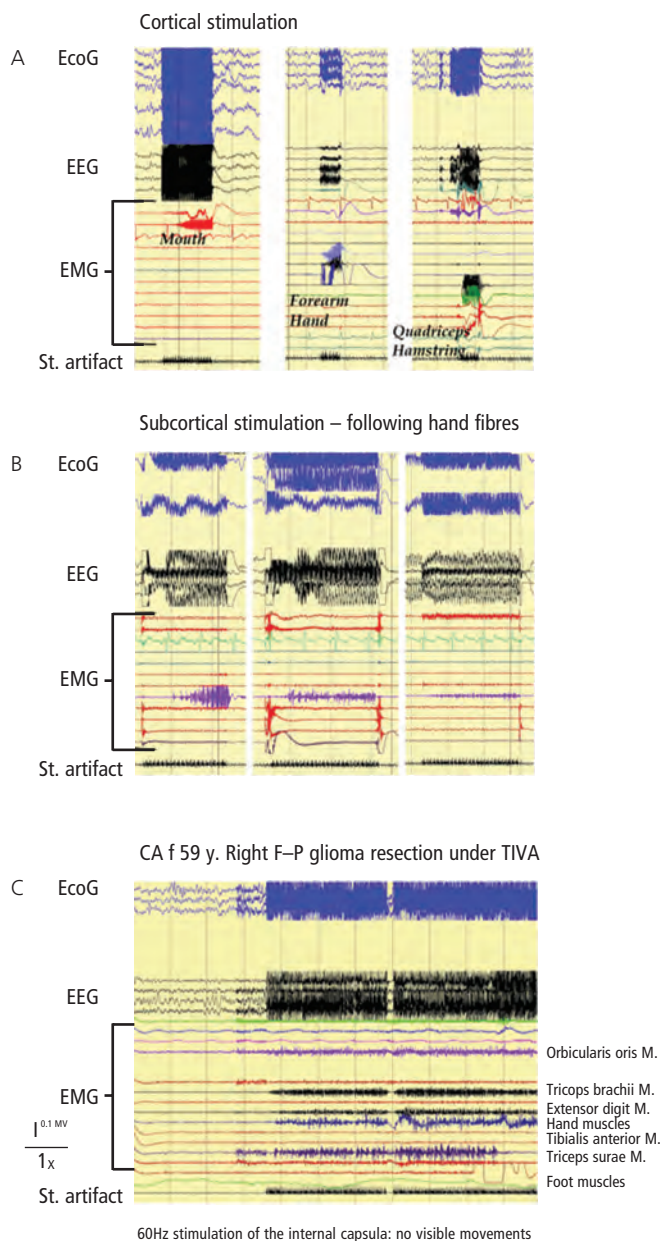
DES for cortical and subcortical mapping is performed using a bipolar hand-held stimulator with 1mm electrode tips 5mm apart, according to Berger and colleagues,⁷ connected to an Ojemann cortical stimulator (Integra Neuroscience) or a Osiris stimulator (Inomed, Germany) delivering biphasic square wave pulses, with each phase lasting 1ms at 60Hz in trains lasting for one to three seconds for cortical mapping and one to 10 seconds for subcortical mapping. Subcortical mapping is alternated with resection in a back-and-forth fashion.

For continuous monitoring of motor pathways, MEPs are collected from the distal muscles after stimulation of the motor cortex with short trains of high-frequency anodal pulses (five to six pulses of 500ms, inter-stimulus interval 4ms). The MEP technique after train-of-five stimulation,⁸ which was first introduced for surgery in anaesthetised patients, has been demonstrated to be adequate for the detection of impending lesions of the motor cortex and of the corticospinal motor pathways. In our procedures, a strip electrode for ECoG containing four to eight electrodes is placed over the precentral gyrus and connected to the Osiris stimulator. In awake patients, a single or a few trains at 1Hz are usually delivered at intervals, with an intensity of stimulation close to motor threshold for MEP without any discomfort to the patient. The muscle MEP has to be recorded with either needle or surface EMG electrodes, with the latter being more convenient in awake patients. MEP recordings are usually alternated with direct cortical motor mapping.

The purpose of the mapping procedure is to reliably test motor, language and cognitive functions. The first step in the mapping procedure is to define the stimulation intensity for DES at 60Hz. As movement is easy to observe, it is advisable to start the procedure with cortical mapping of motor function. The lowest stimulation intensity evoking a motor response (usually in the hand) without evoking corticographic ADs is used in most cases throughout the further mapping of cognitive and language function. Initially, a low current intensity (2mA) is used; this is progressively increased in 0.5mA steps until a muscle response is induced. A stimulation lasting for one or two seconds is usually sufficient to generate a hand motor response from the primary motor area (M1). At this time, it is good practice to stimulate the areas close to the 'hot spot' where the movement was induced in order to map the entire motor strip and to check whether the same current is able to evoke motor responses even there. If not, the current intensity may be increased and adjusted in order to evoke motor responses. It is also good practice to re-check using ECoG whether the applied current induces ADs, i.e. seizure activity, in nearby brain areas. In fact, the current intensity immediately below the threshold inducing ADs should be used for mapping in order to maintain focal stimulation and avoid seizures. If ADs are seen, the current should be reduced, usually by 0.5 or 1mA. In all patients, ECoG recording is then observed throughout the mapping to detect the appearance of ADs in order to ensure the reliability of the test and avoid electrical or clinical seizures. Only the responses evoked in the absence of ADs are considered to be reliable. In cases of mapping performed under general anaesthesia, the current intensity ranges between 5 and 15mA, and the level of anaesthesia, which strongly influences the excitability of the cortex, can be monitored by ECoG. In awake patients, a current intensity ranging between 2 and 8mA is usually sufficient to evoke motor responses.

In visuospatial mapping, the same current used for motor mapping is applied. In this case, the patient is asked to perform a bisection or cancellation test, which includes looking at a touch-screen for the appearance of several lines, with the patient touching the centre of the line (bisection) with a pen. For the cancellation test, the patient is

Figure 1: Examples of Motor Responses During Cortical and Subcortical Motor Mapping

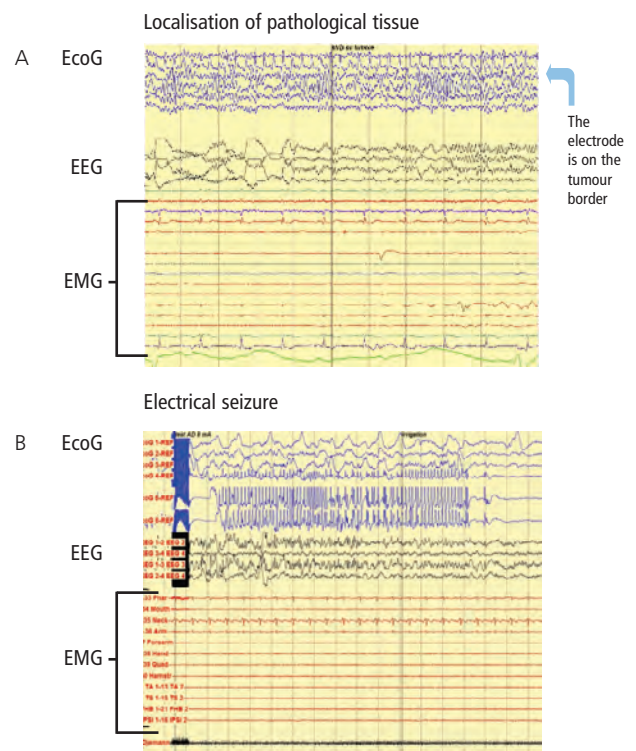


A: Cortical stimulation (60Hz, 4mA): electromyogram (EMG) shows stimulation-induced responses in the mouth, forearm, quadriceps and hamstring, allowing the major components of the motor homunculus to be identified.
B: Subcortical stimulation (60Hz, 6mA): EMG shows that stimulation induces responses in the hand and that hand fibres were followed until the deeper part of resection.
C: Subcortical stimulation in an anaesthetised patient (60Hz, 8mA): EMG shows response in several muscles due to the stimulation of the corticospinal tract at the level of the internal capsule; no overt movements were observed clinically.

again asked to look at the touch-screen for the appearance of stars in the upper or lower right or left section of the screen and to communicate this to the neuropsychologist in the room. In this case, the stimulus is applied just before the line or the stars are presented, and the duration of the stimulus is set up to four seconds.

For language mapping, the current that evoked motor responses is tested. The initial test is counting. The current is usually applied to the facial premotor cortex, and the aim of the test is to check whether the current is able to stop the patient counting. This test has to be repeated several times and the counting has to be stopped at least three times in order to be

Figure 2: Usefulness of ElectroCorticogram and Electroencephalogram Recordings



A: An electrocorticogram (EcoG) allows the identification of spikes in a cortical area close to the tumour border. This area of pathological electrical activity was resected because it was recognised as not functional at the motor and language mapping.
B: An EcoG shows the occurrence of an electrical seizure without electromyogram abnormalities.

reliable. If not, the current intensity is increased until this result is achieved. When the current for language testing is established, the current is applied to the whole brain surface exposed and the occurrence of ADs checked on the ECoG. The duration of the stimulus is between three and four seconds. Only the current that does not induce ADs in the entire brain surface to be mapped is used for mapping. In case of ADs, the current intensity is decreased by at least 0.5ms. The current intensity generally applied for language mapping ranges between 2 and 9mA.

For cortical mapping, it is common practice to stimulate the whole of the exposed cortical area every 5mm², to never stimulate the same cortical area twice successively and to stimulate every site at least three times non-consecutively. For language mapping to identify malcompliance or impairment not related to stimulation, e.g. a non-convulsive seizure, each stimulation should start before the presentation of the material is started. Each stimulation should be followed by at least one task without stimulation; two tasks are the standard. As the duration of the stimulation is usually longer than that for motor mapping (four versus one to three seconds), frequent stimulation might trigger ADs or seizures. During the administration of each test it is important to continuously check the ECoG and EEG for the occurrence of ADs or electrical seizures. A neuropsychologist or speech therapist has to be in the room in order to present the patient with the test (object naming, verb generation, face naming, counting or word or sentence comprehension) and to evaluate the correctness of the responses. Only mistakes in the absence of ECoG disturbances are reliable. In addition, a site can be defined as essential for language when it produces language disturbances at least three times in various non-consecutive stimulations.



OCS2 OJEMANN CORTICAL STIMULATOR



OCS2 OJEMANN IS ESPECIALLY USEFUL FOR CORTICAL STIMULATION PRIOR TO EPILEPSY SURGERY AND FOR INTRAOPERATIVE CORTICAL MAPPING BEFORE CORTICAL INCISION OR PLACEMENT OF DEPTH ELECTRODES IN PATIENTS WITH SEIZURE DISORDERS.

GREATLY SIMPLIFIES
INTRAOPERATIVE CORTICAL MAPPING.

SEVERAL DURATIONS AND RATES
FROM WHICH TO CHOOSE FROM.

ADJUSTABLE AUDIBLE TONE
INDICATES OUTPUT RATE.

WIDE RANGE OF CONSTANT CURRENT OUTPUTS.

PORTABLE, BATTERY-OPERATIVE DESIGN.

Integra Epilepsy™

It is important to keep the surfaces to be stimulated moist and not to stop mapping after identifying only one eloquent site, but rather to search for possible redundancies; a negative mapping does not protect, but creates the problem of questionable stimulation reliability. Stimulation intensity should be decreased during 'control stimulations' in areas of 'decompressed' brain tissues in order to limit the risk of inducing a seizure. During deviation from optimal stimulation intensities, intra-operative ECoG is mandatory.

For subcortical mapping, either the same current used for cortical mapping or a current 2mA higher is applied, and the stimulus is continuously alternated with resection. For motor mapping, the evoked responses are checked either with EMG recording or clinically⁹ (see *Figures 1a* and *1b*). For visuospatial subcortical mapping, the patient is presented with bisection or the cancellation test, and for language subcortical mapping with a language test composed mainly of object naming or verb generation. Again, during subcortical mapping ECoG is continuously monitored to look for the occurrence of ADs and to assess for the occurrence of seizure and the reliability of the responses.

MEP monitoring is usually used at the beginning of the procedure, and helps in identifying the location of the motor strip. During resection, MEP recording is alternated with subcortical motor mapping and provides additional information about the integrity of the motor pathways. In addition, MEP provides warnings of impending brain ischaemia due to critical vessel interruption, mostly in deep temporal or insular regions.

As already stated, EEG and ECoG recordings should be taken throughout the procedure in order to monitor for the occurrence of ADs, electrical seizures or even clinical seizures (see *Figure 2b*). The occurrence of ADs is quite common during these procedures, and the main objective of monitoring is to recognise those that occur in response to stimulation in order to maintain the reliability of the testing. Groups of ECoG spikes or electrical seizures occur in up to 30–40% of cases, and may or may not be related to stimulation. In any case, when they appear it is recommended to irrigate the cortex and the surgical cavity with cold saline, which in the majority of cases results in the control and reversal of the situation. Clinical seizures occur in 10–15% of cases, most of which are focal; the use of cold saline irrigation is able to control and totally revert most of such cases. Therefore, EEG is useful to detect diffusion of the seizure. The few clinical seizures we observed appeared most frequently at the end of tumour resection, when cortical stimulation at 60Hz was applied to assess the integrity of the motor pathway. The current was subsequently reduced, and no further seizures were observed. This stresses the fact that at the end of the surgical resection it may be necessary to reduce the intensity of the current due to the reduction of the mass effect exerted by the tumour on the surrounding functional parenchyma. In selected cases, ECoG can be used to detect the generation of spikes in specific areas of the cortex, whether in close proximity to the tumour mass or otherwise, that are responsible for sustained electrical activity (see *Figure 2a*).

Concluding Remarks

We have presented a neurophysiological protocol that includes EEG, ECoG, EMG, DES and MEP monitoring. This protocol has been successfully applied on 300 consecutive patients treated at our institution over the last three years for surgical resection of gliomas located close to or within motor, visuospatial or language areas or pathways. The majority of these cases were low-grade gliomas (69%), and the patients had a mean age of 37.6 years (range 16–68 years).^{6,10–14} All of the proposed techniques add information that contributes to good outcomes following surgery. There are many advantages of EMG recording:¹⁵ it can be used even in patients under general anaesthesia, provided no muscle relaxant is employed; it allows several muscle groups to be monitored simultaneously; it detects even low-amplitude motor-evoked responses, such as those obtained by low levels of cortical stimulation, thus reducing the risk of seizures, or those evoked by very deep brain stimulation when the surgeon is close to fibres joining the corticospinal tract; and it detects clonic activity at the very beginning of any stimulation-induced seizure.

ECoG is used by neurosurgeons at the beginning of the procedure in order to assess the optimal current for stimulation – that is, the maximal current that does not evoke ADs in the adjacent ECoG recording. Indeed, even later on during tumour resection with brain mapping, ECoG has shown a high sensitivity in detecting epileptic discharges before the development of any EMG activity, thus allowing the surgeon to abort the seizure and avoiding the use of drugs that might affect the whole cortical activity and the mapping procedure. Scalp EEG is recorded in order to obtain information about brain activity in the anaesthetised patients when ECoG recording is not yet or no longer available and seizures may otherwise be undetected, and also to assess brain activity at a distance from the operating field. EEG provides valuable information during the tapering of anaesthesia at the end of craniotomy in awake procedures, as well as at the end of surgery, mostly when a late awakening was observed and seizure activity could otherwise only be suspected. During surgery, when spike activity appeared on ECoG, EEG was observed to detect spike diffusion to different cortical areas ipsi- or contralaterally. In such cases a generalised seizure may be suspected and should be promptly treated. If spike activity is detected only by ECoG adjacent to the resection site, a focal seizure is suspected; this can usually be aborted by cold irrigation of the surgical field.

MEP monitoring provides useful information on the integrity of the motor pathways throughout the procedure, and can also warn of impending brain ischaemia due to critical vessel interruption, mostly in deep temporal or insular regions. In addition, it allows the integrity of the motor pathway at the end of the resection to be assessed, which is always a strong indicator of good prognosis; this is also the case when resections close to motor pathways lead to temporary severe post-operative motor deficits. This protocol is easy to administer and is characterised by a high rate of safety and effectiveness. However, the set-up should be tailored to the characteristics and location of the lesion to be removed, as well as to the patient, in order to achieve the best functional results. ■

- Duffau H, Capelle L, Sichez N, et al., *Brain*, 2002;125:199–214.
- Duffau H, *Expert Rev Neurother*, 2005;5:473–85.
- Duffau H, *Lancet Neurol*, 2005;4:476–86.
- Duffau H, Lopes M, *J Neurol Neurosurg Psychiatry*, 2005;76:845–51.
- Duffau H, *J Neurooncol*, 2006;79:77–115.
- Bello L, Gambini A, Castellano A, et al., *Neuroimage*, 2008;39(1):369–82. Epub 2007 Aug 29.
- Berger MS, Kincaid J, Ojemann GA, Lettich E, *Neurosurgery*, 1989;25:786–92.
- Nakagawa Y, Tamaki T, Yamada H, Nishiura H, *J Orth Sci*, 2002;7:102–10.
- Keles GE, Lundin DA, Lamborn KR, et al., *J Neurosurg*, 2004;100:369–75.
- Bello L, Gallucci M, Fava M, et al., *Neurosurgery*, 2007;60(1):67–80, discussion 80–82.
- Bello L, Acerbi F, Giussani C, et al., *Neurosurgery*, 2006;59(1):115–25, discussion 115–25.
- Carrabba G, Fava E, Giussani C, et al., *J Neurosurg Sci*, 2007;51(2):45–51.
- Carrabba G, Fava E, Mandonnet E, et al., *Neurosurgery*, in press.
- Giussani C, Roux FE, Lubrano V, et al., *Acta Neurochir (Wien)*, 2007;149(11):1109–16, discussion 1116. Epub 2007 Aug 23.
- Yingling CD, Ojemann S, Dodson B, et al., *J Neurosurg*, 1999;91:922–7.